



A mesenteric cyst presenting as a femoral hernia: a case report

Sezgin Mutlu¹, Süleyman Kargin¹, Barış Sevinç^{2*}, Ersin Turan³, Osman Doğru¹

¹Department of General Surgery, Konya Training and Research Hospital, Konya, Turkey, ²Department of General Surgery, Sarıkaya State Hospital, Yozgat, Turkey, ³Department of General Surgery, Yunak State Hospital, Konya, Turkey

ABSTRACT

Mesenteric cysts are a rare phenomenon and can be encountered in different regions of the mesentery or in the retroperitoneal region. They are usually asymptomatic but may lead to a variety of symptoms depending on their site. We report a case of a mesenteric cyst presenting as a femoral hernia, which is, to our knowledge, the second case found in the literature. Forty-eight years old female patient presented with a history of pain and swelling in her left inguinal region for six months. Although femoral hernias are rare conditions, mesenteric cysts can protrude inside the femoral canal. In a case of clinical suspicion of such a condition, appropriate imaging should be performed.

Keywords: Femoral hernia; mesenteric cyst; surgery

INTRODUCTION

Mesenteric cysts are quite rare and only seen in 1/250.000 hospitalized patients (1). It has been found that it has an incidence of 1/20.000 in children and 1/100.000 in adults (2). Mesenteric cysts can be placed anywhere starting from the mesentery of the duodenum down to the mesentery of the rectum, and in rare cases, even in the retroperitoneal region (3). Despite having all these possible locations, they're most frequently observed in the mesentery of the small intestines (4,5). There has been only one previous report in the medical literature of a mesenteric cyst presenting as a

femoral hernia, and our report is the second one on this topic.

CASE REPORT

A 48-year-old female patient presented with a painful swelling on her left groin for 6 months. Besides a laparoscopic cholecystectomy performed 3 years ago, there was no surgical intervention or specific disease in her history. During the physical examination, a swelling of 5 × 4 cm in her left femoral region was palpated. A superficial ultrasonography was performed and a septated cystic mass with lobulated contours of 52 × 23 mm of dimension was detected. Her complete blood count and biochemical test results were within normal range.

Under spinal anesthesia, a classic inguinal hernia incision was performed and by dissecting the aponeurosis of the external oblique muscle, the inguinal

*Corresponding Author: Barış Sevinç, M.D., Sarıkaya State Hospital, Yozgat, Turkey Phone: 00905054880511, E-mail: drbarissevinc@gmail.com

Submitted: 19 November 2015 / Accepted: 12 November 2015

DOI: <http://dx.doi.org/10.17532/jhsci.2016.284>



canal was reached. Then the transverse fascia was dissected and the preperitoneal region was reached. During exploration, a cystic lesion of 5 × 3x3cm originating from the mesentery and protruding towards the femoral canal was observed (Figure 1). The cyst was excised and the remaining mesenteric tissue was placed into the abdominal cavity. A McVay repair procedure was performed on the region of the femoral hernia. The content of the cyst was emptied and serous fluid came out of it. After bleeding control, the transverse fascia was closed with a polyglycolic acid suture and the external oblique muscles fascia was closed with a prolene suture. The skin was sutured intradermally. There were no complications on the patient's postoperative first day. The patient could tolerate oral intake and was discharged without further complications. The excised mass was then reported as a mesenteric cyst by the histopathological examination (Figure 2).

DISCUSSION

Although there have been reports of malignant transformation, mesenteric cysts are benign lesions. Mesenteric cysts are rare lesions, mostly seen in children. The mentioned studies report rare transformations to lymphangiosarcoma, malignant teratoma and even adenocarcinoma (6). Their etiology has been found to be very various (7,8). They usually occur after traumatic events, due to abnormalities in the mesenteric tissue. In our case, we could not identify the etiologic factor that would lead a mesenteric cyst in the femoral canal. Simple lymphatic or mesenteric cysts are of congenital origin, but benign cystic mesotheliomas are frequently associated with previous abdominal surgery, pelvic inflammatory disease and endometriosis (8). Also, mesenteric cysts are more frequent in females and after the fifth decade (9). In our patient, the onset age and gender were similar as literature. They are usually asymptomatic but may lead to a variety of symptoms (non-specific pain 82%, nausea 45%, vomiting 45%, constipation 27%, diarrhea 6% and palpable abdominal mass in 61% of cases) according to their site (10). Some patients might present themselves with complications like torsion, hemorrhage, and cyst rupture. Their optimal treatment is surgery and they have a very good prognosis. There are no reports of any post-op recurrences.

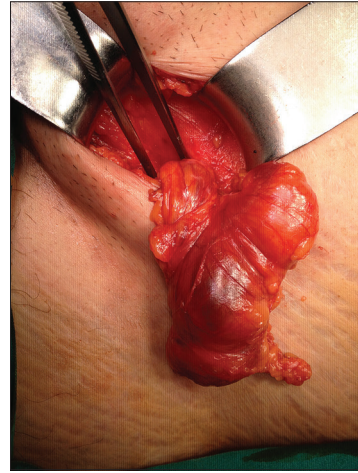


FIGURE 1. Perioperative appearance of a mesenteric cyst protruded into the femoral canal

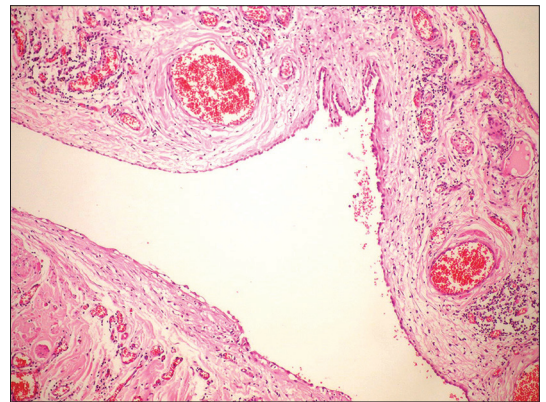


FIGURE 2. Cystic lesion lined with single layer epithelium (H&E x100)

Mesenteric cysts occur mostly on the small intestine but can be seen anywhere from the duodenum to the rectal region (11). In a study performed by Arnold et al. between 1978 and 1997, 133 patients with mesenteric cysts were analyzed. Sixty-eight percent of cysts (91) were situated inside the mesentery, 18% (24) in the omentum and 14% (18) in the retroperitoneal region (12). So far there have been 5 cases of reported mesenteric cysts in the inguinal region and only 1 in the femoral region (13).

Femoral hernias compose 6–17% of all abdominal wall hernia (14-16) and they are generally palpated as a mass on the lateral of the pubic tubercle.

Previous studies have shown that inside the femoral canal the appendix, small intestine, omentum, Meckel's diverticulum, adnexa and even ectopic testis could protrude (16).

The first to report a case like the current one was by Dellaportas et al. Their case was an inclusion cyst characterized as an irreducible femoral hernia (13). Therefore, this is the second reported case in the medical literature of a mesenteric cyst characterized as an irreducible femoral hernia. Our patient presented with nonspecific symptoms of a mesenteric cyst and on ultrasonography it was reported as a simple cyst. The final diagnosis was possible only during the surgery, where the cyst was excised and a classic hernia procedure was applied.

CONCLUSION

Although femoral hernias are rare conditions, mesenteric cysts can protrude into the femoral canal. In case of clinical suspicion of such a condition, appropriate imaging for accurate diagnosis should be performed.

CONFLICT OF INTEREST

The authors declare that they have no competing interests.

REFERENCES

- Miliras S, Trygonis S, Papandoniou A, Kalamaras S, Trygonis C, and Kiskinis D. Mesenteric cyst of the descending colon: report of a case. *Acta Chir Belg*. 2006; 106(6):714-6
- Kurtz RJ, Heimann TM, Holt J, Beck AR. Mesenteric and retroperitoneal cysts. *Ann Sur*. 1986; 203(1): 109-12 <http://dx.doi.org/10.1097/0000658-198601000-00017>
- Bodakçı MN, Hatipoğlu NK, Fırat U, Penbegül N, Atar M. A case of a scrotal mesenteric cyst. *Dic Med J*. 2014; 41(1): 214-6 <http://dx.doi.org/10.5798/diclemedj.0921.2014.01.0402>
- Hassan M, Dobrilovic N, Korelitz J. Large gastric mesenteric cyst: case report and literature review. *Am Surg*. 2005; 71(7): 571-3.
- Şahin DA, Akbulut G, Saykol V, San O, Tokyol C, Acik D. Laparoscopic enucleation of mesenteric cyst: a case report. *Mt Sina J Med* 2006; 73(7): 1019-20
- Daly JM., Adams JT, Fantini GA, Fisher JE. Abdominal Wall, Omentum, Mesentery and Retroperitoneum. In: SCHWARTZ S. I. et al. *Principles of Surgery*. 7th ed. McGraw-Hill, 1999, pp: 1576-8.
- Al Mulhim AA. Laparoscopic excision of a mesenteric cyst during pregnancy. *JSLs* 2003; 7(1): 77-81.
- Dursun AS, Gokhan A, Volkan S, Osman S, Cigdem T, Osman ND. Laparoscopic enucleation of mesenteric cyst: A case report. *Mt Sinai J Med*, 2006; 73(7): 1019-20
- Bhandarwar AH, Tayade MB, Borisa AD, Kasat GV. Laparoscopic excision of mesenteric cyst of sigmoid mesocolon. *J Min Access Surg*, 2013; 9(1): 37-9. <http://dx.doi.org/10.4103/0972-9941.107138>
- Prakash A, Agrawal A, Gupta RK, Sanghvi B, and Parelkar S. Early management of mesenteric cyst prevents catastrophes: a single centre analysis of 17 cases. *Afr J Paediatr Surg*, 2010; 7(3): 140-3 <http://dx.doi.org/10.4103/0189-6725.70411>
- Liew SC, Glenn DC, Storey DW. Mesenteric Cyst. *Aust N Z J Surg*, 1994; 64p(11):741-4 <http://dx.doi.org/10.1111/j.1445-2197.1994.tb04530.x>
- Coran, Arnold G., et al. *Pediatric Surgery: Expert Consult-Online and Print*. Vol. 2. Elsevier Health Sciences, 2012.
- Dellaportas D, Polymeneas G, Dastamani C, Kairi-Vasilatou E, Papaconstantinou I. Strangulated femoral hernia turned to be peritoneal cyst. *Case Rep Surg*. 2012;2012:528780. <http://dx.doi.org/10.1155/2012/528780>
- Mohanty SK, Bal RK, Maudar KK. Mesenteric cyst—an unusual presentation. *J Pediatr Surg*, 1998; 33sw(5):792-3 [http://dx.doi.org/10.1016/S0022-3468\(98\)90224-X](http://dx.doi.org/10.1016/S0022-3468(98)90224-X)
- Popli MB, Garg DP, Anand R, Jain M, Jain N, Mahajan R. Retroperitoneal lymphangioma presenting as an inguinal Hernia. *Indian Pediatr*, 1994; 31(12): 1574-5
- Gurer A, Ozdogan M, Ozlem N, Yildirim A, Kulacoglu H, Aydin R. Uncommon content in groin hernia sac. *Hernia*, 2006; 10(2):152-5. <http://dx.doi.org/10.1007/s10029-005-0036-4>