

Acute postoperative pain relief, by intraperitoneal application of local anesthetics, during laparoscopic cholecystectomy

Ljiljana Gvozdenović^{1*}, Vesna Pajtić², Dejan Ivanov³, Radovan Cvijanović³, Sava Gavrilović¹, Zoran Gojković⁴, Saša Milić⁵

¹ Clinic of Anaesthesiology and Intensive Care Medicine, Clinical Center of Vojvodina, Hajduk Veljkova 1, 21 000 Novi Sad, Republic of Serbia. ² Urgent Center, Clinical Center of Vojvodina, Hajduk Veljkova 1, 21 000 Novi Sad, Republic of Serbia. ³ Clinic of Abdominal and Endocrine surgery, Clinical Center of Vojvodina, Hajduk Veljkova 1, 21 000 Novi Sad, Republic of Serbia. ⁴ Clinic of Orthopaedic surgery and Traumatology, Clinical Center of Vojvodina, Hajduk Veljkova 1, 21 000 Novi Sad, Republic of Serbia. ⁵ Emergency Medical Service, Health Centre of Indija, J. Dučića 8, 22 000 Indija, Republic of Serbia

Abstract

Introduction: Intraperitoneal administration of local anesthetic in combination with an opioid, for the relief of postoperative pain, has already been reported after laparoscopic cholecystectomy. This study aimed to assess the analgesic effect of the intraperitoneal administration of bupivacaine and morphine, in patients undergoing laparoscopic cholecystectomy.

Methods: 90 patients (30 patients in each group) were included in a double blind, randomized manner. At the end of laparoscopic cholecystectomy, the patients were intraperitoneally treated with 30 ml of: physiological saline (Group 1) or 0.25% bupivacaine (Group 2) or 0.25% bupivacaine + 2 mg morphine (Group 3). Patient's postoperative pain was evaluated using a visual analogue scale and a verbal rating score. The postoperative analgesic requirement was assessed by the total dose of Ketorolak, administered by intravenous or intramuscular route. Pain, vital signs, supplemental analgesics consumption and side effects were recorded for all patients for 12h.

Results: There were no difference between the three groups, regarding pain scores (et rest and coughing) during the study, except in the first 6 h, when scores were lower for patients receiving intraperitoneal bupivacaine + morphine ($p < 0.05$).

Conclusions: In the patients undergoing laparoscopic cholecystectomy, the intraperitoneal administration of bupivacaine + morphine, reduced the analgesic requirements during the first 6 postoperative hours compared with the control groups. The combination of intraperitoneal bupivacaine 0.25% and morphine was more effective for treatment of pain after laparoscopic cholecystectomy.

© 2011 All rights reserved

Keywords: *laparoscopic cholecystectomy, bupivacaine, opioids, morphine, anesthetics, local anesthetics, pain, surgery.*

Introduction

Laparoscopic cholecystectomy (LC) is currently considered to be a relatively minor operation (1,2). It has been classified as a basket procedure (analogous to shopping with a supermarket basket) in the UK government's publications on day-surgery (3). But, an important factor that limits recovery

is postoperative pain. Intraperitoneal instillation of local anesthetics is a simple method of analgesia and should be considered in addition to other morphine sparing analgesics such as NSAIDs, acetaminophen and incisional local anesthetics (4, 5). Laparoscopic cholecystectomy, in healthy patients is routinely performed at our hospital on a day case basis. Intraperitoneal instillation of local anesthetic around the operative site has been used as an analgesic technique on the premise that conduction from visceral sites is blocked and may reduce the extent of referred pain to the shoulder, which results of nerves C3, C4, C5 dia-

* Corresponding author: Prof dr Ljiljana Gvozdenović, Clinic of Anaesthesiology and Intensive Care Medicine, Clinical Centre of Vojvodina, Hajduk Veljkova 1, 21000 Novi Sad, Republic of Serbia Tel: +38163-529-409, Fax: +38121-423-902; E-mail: profgvozdenovic2010@hotmail.com

phragm innervation, gas distension and diaphragmatic shifting, in the postoperative period (5,6,7). However, in previous studies of intraperitoneal local anesthetics following laparoscopic cholecystectomy it has not been possible consistently to demonstrate reliable analgesic effects (8,9,10). This may be related to nociceptive conduction from incisional sites that are not blocked by local anesthetics given into the intraperitoneal cavity. Different regimens have been proposed to relieve pain after laparoscopic surgery, such as non-steroidal anti-inflammatory drugs, local wound anesthetics, intraperitoneal anesthetics and saline, gas drainage, heated gas low-pressure gas and nitrous oxide pneumoperitoneum.. Multimodal analgesia (combined use of two or more analgesic agents) for pain relief after operation is believed to be more advantageous than single modality treatment, especially when different sites of action are involved, or when a synergistic effect, or both, is achieved (11,12). The aim of the present study was to determine the efficacy of the intraperitoneal application of bupivacain-morphine.

Methods

Patients and Procedures

A prospective, randomized, double-blind study was undertaken with written informed consent which was obtained from all patients. Each study group consisted of 30 ASA I-II patients scheduled to undergo elective LC for cholelithiasis under general anesthesia. The individuals, of both sexes, were aged 26-63 yr. Criteria for exclusion were: psychiatric disease, allergic reactions to drugs or local anesthetics, morbid obesity and severe chronic disease. Patients were also excluded, if they underwent surgery for acute cholecystitis or if the operation was converted to an open procedure. All patients were given a standard anesthetics comprising propofol 2-4 mg/kg, fentanyl 2 µg/kg, ondasetron 4 mg, i.v., Rocuronium 0.6 mg/kg was used for muscular relaxation. Patients lungs were ventilated without nitrous oxide, but with sevoflurane 1-1.5%, with oxygen. Suppositories of diclofenac 100 mg, were administered at the induction of anesthesia. Standard patient monitoring was used. Lung ventilation was adjusted to maintain an end-tidal carbon di-

oxide partial pressure of 4.7-5.3 kPa. Intra-abdominal pressure during laparoscopy was automatically maintained at 12 mmHg by a CO2 insufflator. At the end of successful LC, patients were allocated randomly to one of three groups. Group 1 (n=30) received physiological sodium chloride 30 ml, intraperitoneally. Group 2 (n=30) bupivacaine 0.25% 30 ml intraperitoneally. Group 3, (n=30) bupivacaine 0.25% 30 ml, intraperitoneally plus morphine 2mg. Each patient received the test solution in the following way: 15 ml was sprayed to both sides of the diaphragm, and another 15 ml, was directly applied to the gall bladder bed and to the right subhepatic space. All patients received ondasetron i.v., during operation (13). During closure of the wound, the incisional sites were infiltrated with bupivacaine 20 ml, 0.25%, 2.5 mg/ml, with epinephrine 5 µg/ml, in all patients (14). Residual neuromuscular blockade was antagonized with a mixture of neostigmine and atropine (15). In the postoperative period, patients were assessed on awakening and then at 1, after 6 and after 12 hours by a trained observer. Intraperitoneal pain at rest and during deep inspiration and any pain in the right shoulder were assessed on a visual analogue scale (VAS). The degree of postoperative pain was assessed with a VAS (0-100 mm) (0 - no pain, 100 - severe pain) at rest and on coughing. Patients were asked about the location of pain, whether at the shoulder, incision sites and/or inside the abdomen. Pain relief was rated by the patients on a 4 point verbal rating score (VRS). 0 = no pain relief; 1 = partial pain relief; 2 = good pain relief; 3 = excellent pain relief, complete analgesia. The VRS recorded during the study was summed obtaining the total pain relief score for that period. Total pain relief scores were used widely in analgesic clinical trials – higher scores signifying better analgesia. Nausea and sedation were assessed also on a similar VAS, representing “no nausea” and “fully awake” on the left and “worst imaginable nausea” and “very drowsy” on the right, respectively. Pain, sedation and nausea scores for the first 6 h after operation were summed (11, 24).

Statistical analysis

Nominal data were analyzed with the χ^2 -test. Statistical analyses was performed with the software SPSS. $p < 0.05$ was considered significant.

TABLE 1. Patients characteristics

	Group 1	Group 2	Group 3
Gender (m/f)	3/27	4/26	3/27
Age (yr)	46 (13)	48 (13)	50 (9)
Height (cm)	164 (4)	164 (7)	165 (7)
Weight (kg)	75 (8)	81 (7)	78 (13)
Duration of pneumoperitoneum	57 (13)	68 (20)	66 (21)

Results

The groups were similar in regard to gender, age, height, weight and duration of the pneumoperitoneum (Table 1).

Values are mean (\pm SD). There were no significant differences between groups. There were no significant differences between the three groups in relation to pain scores (at rest or on coughing) during the study except in the first 6 h, in regard to incisional and intra-abdominal pain scores, respectively, in which pain was significantly lower ($p < 0.05$) in those patients receiving intraperitoneal bupivacaine plus morphine (Figure 1). Scores of 2 (good relief) or 3 (complete relief) on the VRS were reported more often by pa-

tients in Group 3, which resulted in higher total pain relief scores, although the differences were not significant after six hours (Figure 2). 26 patients of the Group 1, 16 in Group 2 and 2 in Group 3 needed a rescue dose, of postoperative analgesic drugs, in the first 6 h. No differences in the incidence of nausea/vomiting were observed between groups (40%, 33%, and 40% in Groups 1, 2 and 3, respectively). None of the other above-mentioned side-effects was reported by any of the groups.

Discussion

The results of this study demonstrated that intraperitoneal administration of bupivacaine 0.25% 30 ml, plus morphine 2mg, significantly reduced postoperative analgesic requirements during the first 6 h, after laparoscopic cholecystectomy, compared with the control group. Furthermore, the analgesic requirements were significantly lower during the entire study in patients belong to Group 3, who received intraperitoneal bupivacaine 0.25% 30 ml, plus morphine at the end of surgery. Accordingly, previously we injected the drugs to the subdiaphragmatic area. However, we found a low incidence of shoulder pain in all treatment groups, because the residual intraperitoneal carbon dioxide was deflated carefully by the surgeon. Our study shows that the intraperitoneal administration of bupivacaine is effective after LC, as noted in other reports, although the amount of pain reduction and duration of effect

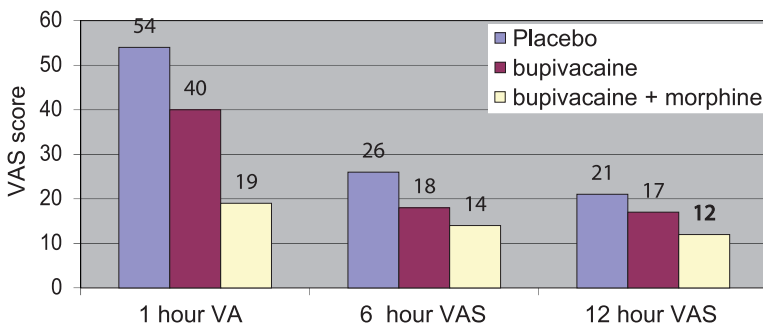


FIGURE 1. VAS score at placebo, bupivacaine and bupivacaine+morphine group.

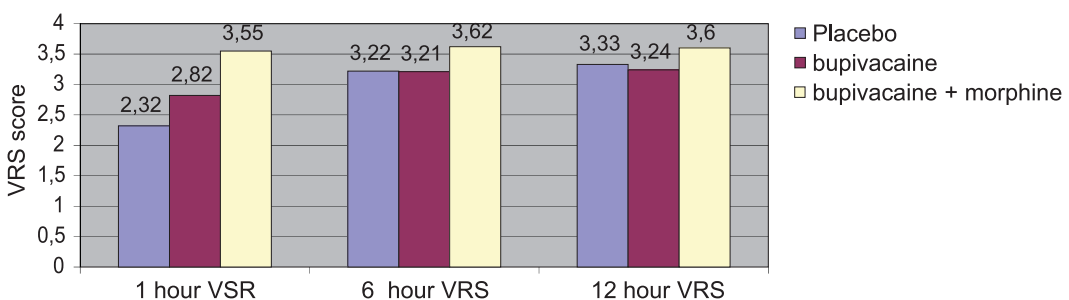


FIGURE 2. VRS score at placebo, bupivacaine and bupivacaine+morphine group.

were limited (16-19). It has been suggested that the poor results in pain reduction, when intraperitoneal local anesthesia is used, after LC – compared with those in the available gynecological literature - are due to visceral and parietal pain being more severe than shoulder pain after LC (20-24). On the other hand, in a recent study the intraperitoneal instillation of bupivacaine during LC resulted in lower pain scores and in reduced morphine requirements compared with placebo. We used ketorolak, a non-opioid analgesic with minor adverse effects and with powerful pain-relieving activity, including surgical pain, in our study to assess analgesic requirements after operation. Our data also showed a significant decrease in supplemental ketorolak in patients given morphine intraperitoneal. We used bupivacaine and low doses of morphine, intraperitoneally to achieve the additional analgesic benefit from the combined effect of a local anesthetic with an opioid agonist (25-29). Intraperitoneal local anesthetics would be expected to be useful for treating visceral pain. In our study it is likely that intraperitoneal bupivacaine in the right hypochondrial area had an analgesic effect (30). It significantly reduced total abdominal pain during inspiration and there was a trend towards lower scores for total abdominal pain at rest and total both shoulder pain. Local anesthetic toxicity is a serious problem, which limits dosage and efficacy. Bupivacaine is used traditionally as it has a long duration of action. It can cause central and cardiovascular toxicity and there have been reports of accidental deaths and cardiac arrest (36). We did not observe any side-effects attributable to the local anesthetic. We did not measure plasma

concentrations of bupivacaine, but several reports have shown that the range of mean plasma concentration (0.92 – 1.14 µg/ml) after the intraperitoneal administration of plain bupivacaine (100 – 150 mg) is well below the toxic concentration of 3 µg/ml. The doses of bupivacaine in our study were lower than those thought to cause systemic toxicity. Our results are consistent with other studies in which intraperitoneal administration of local anesthetic has been shown to have a modest analgesic effect (31, 32). Of 13 clinical trials considered in a systemic review it was found that the intraperitoneal administration of bupivacaine 50-200 mg, in volumes of 10-100 ml, produced significant analgesia in seven studies where supplemental analgesic consumption was significantly reduced (33-35). In summary, we have demonstrated that the intraperitoneal administration of morphine plus bupivacaine 0.25% in patients undergoing laparoscopic cholecystectomy reduces ketorolak requirements during first 6 h after the operation compared to a control group. However, the intraperitoneal application of bupivacaine 0.25% combined with morphine, at the end of surgery is effective in achieving reduction in pain (36, 37, 38).

Conclusion

Therefore, we concluded that combination of intraperitoneal bupivacaine and morphine was better than, bupivacaine without morphine, or placebo, for pain relief after laparoscopic cholecystectomy. The surgeons involved in the study continue to use this method of analgesia as part of their routine practice (40, 41).

Competing interests

Authors declare no conflict of interest.

References

1. Ng A, Parker J, Toogood L, Corron BR, Smirh G. Does the opioid-sparing effect of rectal diclofenac following rotal abdominal hysterectomy benefit the patient. *Br Anaesth* 2002; 88: 714-716.
2. Ng A, Smith G, Davidson AC. Analgesic effects of parecoxib following total abdominal hysterectomy. *Br Anaesth* 2003; 90: 746-749.
3. Ng A, Swami A, Smirh G, Davidson AC. The analgesic effects of intraperitoneal and incisional bupivacaine with epinephrine after rotal abdominal hysterectomy. *Anesth Analg* 2002; 9: 158-162.
4. Pasqualucci A, de Angelis V, Contardo R, et al. Preemptive analgesia: intraperitoneal local anesthetic in laparoscopic cholecystectomy. A randomized, double-blind, placebo controlled study. *Anesthesiology* 1996; 8: 11-20.
5. Elhakim M, Elkort M, Ali NM, Tahoun HM. Intraperitoneal lidocaine for postoperative pain after laparoscopy. *Acta Anaesthesiol Scand* 2000; 44: 280- 284.
6. Gvozdrenović Lj, Cvijanović R, Kolak R, Pjević M, Gavrilović S, Veljković R,

- Korica M. Anesthesiology in current world of laparoscopic surgery. *Medicina danas*, 2003; 2(3-4): 298-301.
7. Raetzell M, Maier C, Schroder D, Wulf H. Intraperitoneal application of bupivacaine during laparoscopic cholecystectomy - risk or benefit? *Anesth Analg* 1995; 81: 967-972.
 8. Scheinin B, Kellokumpu I, Lindgren L, Haglund C, Rosenberg PH. Effect of intraperitoneal bupivacaine on pain after laparoscopic cholecystectomy. *Acta Anaesthesiol Scand* 1995; 39: 195-198.
 9. Joris J, Thiry E, Paris P, Weerts J, Lamy M. Pain after laparoscopic cholecystectomy: characteristics and effect of intraperitoneal bupivacaine. *Anesth Analg* 1995; 81: 379-384.
 10. Elfberg BA, Sjoval-Mjoberg S. Intraperitoneal bupivacaine does not effectively reduce pain after laparoscopic cholecystectomy: a randomized, placebo-controlled and double-blind study. *Surg Laparosc Endosc Percutan Tech* 2000; 10: 357-359.
 11. Jevitić M, Milovanović D. Fiziološke i fizioterapeutske osnove bola. *Medicinski časopis*, 2006; 1: 54-58.
 12. Zmora O, Srolík-Dollberg O, Barzakai B, et al. Intraperitoneal bupivacaine does not attenuate pain following laparoscopic cholecystectomy. *J Soc Laparoendoscopic Surg* 2000; 4: 301-304.
 13. Moiniche S, Jorgensen H, Wetterslev J, Dahl JB. Local anesthetic infiltration for postoperative pain after laparoscopy: a qualitative and quantitative systematic review of intraperitoneal, port-site infiltration and mesosalpinx block. *Anesth Analg* 2000; 90: 899-912.
 14. Davidov M, Sečen S. Usporedna analiza laparoscopske i klasične holecistektomije u akutnoj upali žučne kese. *Medicina danas*, 2009; 8: 261-275
 15. Breslin DS, Marrin G, Macleod DB, D'ercole F, Grant SA. Central nervous system toxicity following the administration of levobupivacaine for lumbar plexus block: a report of two cases. *Reg Anesth Pain Med* 2003; 28: 144-147.
 16. Jorgensen JO, Gillies RB, Hunr DR, Caplehorn JR, Lumley T. A simple and effective way to reduce postoperative pain after laparoscopic cholecystectomy. *J. of Surg* 1995; 6: 466-469.
 17. Wills VL, Hunt DR. Pain after laparoscopic cholecystectomy. *Br J Surg* 2000; 87: 273-284.
 18. Helvacioğlu A, Weis R. Operative laparoscopy and postoperative pain relief. *Fertil Steril* 1992; 57: 548-552.
 19. Goldsrein A, Grimault P, Henique A, Keller M, Fortin A, Darai E. Preventing postoperative pain by local anesthetic instillation after laparoscopic gynecologic surgery: a placebo controlled comparison of bupivacaine and ropivacaine. *Anesth Analg* 2000; 91: 403-407.
 20. Schulte-Steinberg H, Weninger E, Jokisch D, et al. Intraperitoneal versus interpleural morphine or bupivacaine for pain after laparoscopic cholecystectomy. *Anesthesiology* 1995; 82: 634-640.
 21. Colbert ST, Moran K, O'Hanlon DM, Chambers F, Moriarty DC, Blunnie WP. An assessment of the value of intraperitoneal meperidine for analgesia postlaparoscopic ruballigation. *Anesth Analg* 2000; 91: 667-670.
 22. Ivanov D, Cvijanović R, Major-Zoričić Z, Ivanov M. Usporedna analiza gasnih vrednosti u neposrednom postoperativnom periodu nakon otvorene i laparoscopske holecistektomije *Medicina danas* 2004, (3-4): 194-205.
 23. Kehlet H, Dahl JB. The value of 'multimodal' or 'balanced analgesia' in postoperative pain treatment. *Anesth Analg* 1993; 73: 1048-1056.
 24. Mamhra S, Thisted R, Foss J, Ellis JE, Roizen ME. A proposal to use confidence intervals for visual analog scale data for pain management to determine clinical significance. *Anesth Analg* 1993; 77: 1041-1047.
 25. Loughney AD, Sarma V, Ryall EA. Intraperitoneal bupivacaine for relief of pain following day case laparoscopy. *Br. Obstet Gynaecol* 1994; 101: 449-451.
 26. Chundrigar T, Hedges AR, Morris R, Stamatakis JD. Intraperitoneal bupivacaine for effective pain relief after laparoscopic cholecystectomy. *Ann R Coll Surg Engl* 1993; 75: 437-439.
 27. Mraovic B, Jurisic T, Kogler-Majeric V, Sustic A. Intraperitoneal bupivacaine for analgesia after laparoscopic cholecystectomy. *Acta Anaesthesiol Scand* 1997; 41: 193-196.
 28. Pasqualucci A, de Angelis V, Contardo R, et al. Preemptive analgesia: intraperitoneal local anesthetic in laparoscopic cholecystectomy. A randomized, double-blind, placebo controlled study. *Anesthesiology* 1996; 85: 11-20.
 29. Tsimoyiannis EC, Glantzounis G, Lekkas ET, Siakas P, Tzourou H. Intraperitoneal normal saline and bupivacaine infusion for reduction of postoperative pain after laparoscopic cholecystectomy. *Surg Laparosc Endosc* 1998; 8: 416-420.
 30. Moiniche S, Jorgensen H. Local anesthetic infiltration for postoperative pain relief after laparoscopy: a qualitative and quantitative systematic review of intraperitoneal, port-site infiltration and mesosalpinx blocs. *Anesth Analg* 2000; 90: 899-912.
 31. Labaille T, Mazoit IX, Paqueron X, Franco D, Benhamou D. The clinical efficacy and pharmacokinetics of intraperitoneal ropivacaine for laparoscopic cholecystectomy. *Anesth Analg* 2002; 94: 100-105.
 32. Torres L, Rodriguez M, Montero A, et al. Efficacy and safety of dipyrone versus tramadol in the management of pain after hysterectomy: a randomized, double-blind, multicenter study. *Reg Anesth Pain Med* 2001; 26: 118-124.
 33. Armstrong P, Morton C, Nimmo A. Pethidine has a local anaesthetic action on peripheral nerves in vivo. Addition to prilocaline 0.25% for intravenous regional anaesthesia in volunteers. *Anaesthesia* 1993; 48: 382-386.
 34. Antonijević I, Mousa SA, Schafer M, Stein C. Perineurial defect and peripheral opioid analgesia inflammation. *J of Neurosci* 1995; 15:165-172.
 35. Ng A, Smith G. Intraperitoneal administration of analgesia: is this practice of any utility. *Br J Anaesth* 2002; 89: 535-537.
 36. Suhocki PV, Meyers WC. Injury to aberrant bile ducts during cholecystectomy: a common cause of diagnostic error and treatment delay. *Am J Roentgenol* 1999;172:955-959.
 37. Braghetto I, Bastias J, Csendes A, Debandi A. Intraperitoneal bile collections after laparoscopic cholecystectomy: causes, clinical presentation, diagnosis, and treatment. *Surg Endosc* 2000;14:1037-1041.
 38. Lee VS, Chari RS, Cucchiario G, Mezers WC. Complications of laparoscopic cholecystectomy. *Am J Surg* 1993;165:527-532.
 39. Johansson M, Thune A, Blomqvist A, Nelvin L, Lundell L. Management of acute cholecystitis in the laparoscopic

- ic era: re-sults of a prospective randomized clinical trial. *J Gastrointest Surg* 2003;7:642-645.
40. Ivanov D, Cvijanović R, Major-Zoričić Z, Ivanov M, Veljković R. Klasična naspram laparoscopske holecistektomije: uporedna analiza respiratorne funkcije *Medicina danas*, 2003; 2 (1-2): 114-123.
41. Albright GA. Cardiac arrest following regional anesthesia with etidocaine or bupivacaine. *Anesthesiology* 1979;1: 285-287.