



Bilateral Epididymal Cyst in 14 year-old Boy: a case report

Yiğit Akin¹, Mehmet Sarac², Isil Basara³, Selcuk Yucel⁴, Ahmet Kazez²

¹Department of Urology, Harran University School of Medicine, 63100, Sanliurfa, Turkey. ²Department of Pediatric Surgery, Firat University School of Medicine, 23042, Elazig, Turkey. ³Department of Radiology, Harput State Hospital, 23050, Elazig, Turkey. ⁴Department of Urology, Akdeniz University School of Medicine, 07059, Antalya, Turkey.

ABSTRACT

Bilateral epididymal cysts are rare in childhood. Clinically they may present as acute scrotum and should be differentiated from other pathologies. Herein, we report bilateral epididymal cysts in a 14-year-old boy. He was admitted to emergency department with symptoms of acute left scrotum. There was no history of trauma or infection. Blood analyses, including testis tumor markers were unremarkable. Bilateral epididymal cysts were diagnosed on ultrasonography evaluation. Medical treatment did not stop his scrotal pain. During scrotal exploration, there was no evidence of testicular torsion or any other pathology. An excision of cyst was performed. Histopathologically, the cyst wall was lined by columnar epithelia. As a result of these findings, a pathological diagnosis of epididymal cyst was made. The synchronized evaluation of clinical and ultrasonography findings with an appropriate histopathological evaluation can usually diagnose this rare pathology.

Keywords: Epididymal cyst, microsurgery, pediatrics.

INTRODUCTION

Scrotal masses can be diagnosed by transillumination or a scrotal ultrasonography examination. At transillumination these masses may show primarily fluid, such as a tense hydrocele, or solid, such as testicular tumors. If a much firm intratesticular mass is palpated, evaluation for lymphoma, leukemia, or metastatic disease should be performed with examination of the lymph nodes. Children with a non-tender testicular mass and signs of precocious puberty

should be evaluated for a Leyding cell tumor or less commonly a Sertoli cell tumors (1, 2). Epididymal cysts may present as extratesticular masses but they are usually smooth, round, and characteristically located within the epididymis (2). They cause acute scrotum which is referred as the new onset of pain, swelling, and/or tenderness of intrascrotal contents. Herein, we report that a 14-year-old boy with acute scrotum. Bilateral epididymal cysts were diagnosed at emergency department.

CASE REPORT

A 14 year-old-boy was admitted emergency outpatient clinic with painless left hemi-scrotal enlargement. There was no history of scrotal trauma or in-

*Corresponding author: Yiğit Akin, MD.

Assistant Professor of Urology
Harran University School of Medicine, 63100 Sanliurfa, Turkey
Tel: +90-506-5334999
E-mail: yigitakin@yahoo.com

Submitted October 21, 2014/Accepted March 30, 2014



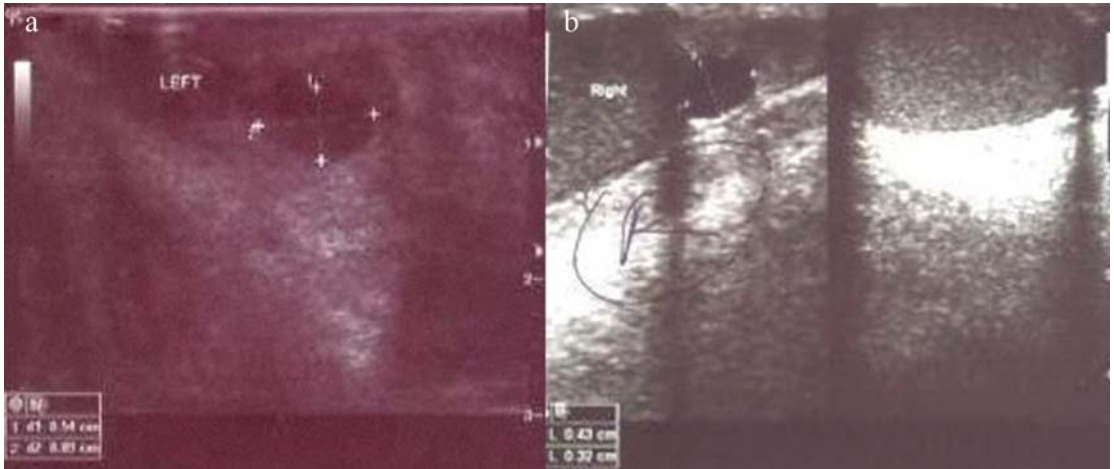

FIGURE 1. Ultrasonographic view of epididymal cyst. a. On the left side, left epididymal cyst size 9x7mm, b. On the right side right epididymal cyst size 4,5x3mm.

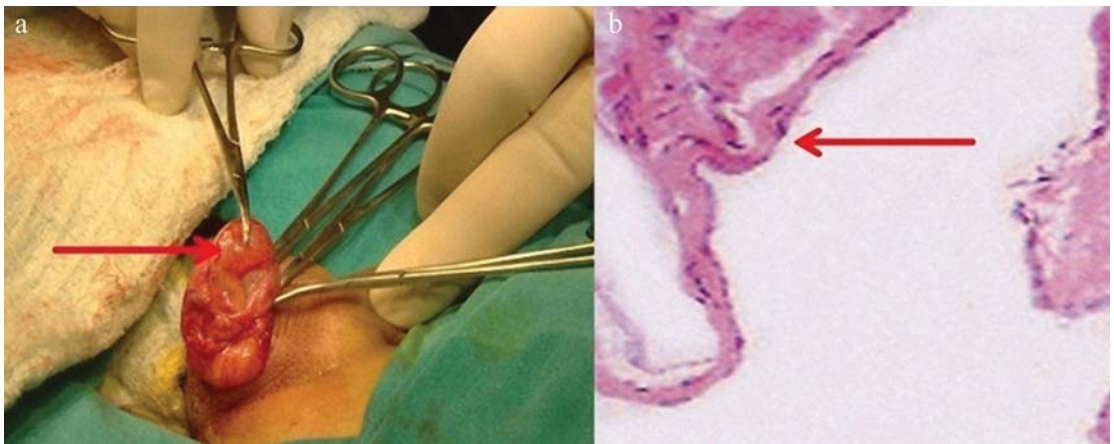


FIGURE 2. Operational and pathological view of cysts a. The arrow and clemp shows epididymal cyst. b. Hispatological findings are, the low columnar epiteliium are spreaded by the wall of cyst, arrow. (HEX400).

fection. At physical examination, in left epididymal zone a nodular mass was palpated without enlargement and tenderness of the testis. Additionally, there was a round small cyst palpated in the right epididymis. In scrotal Doppler ultrasonography, there was no findings of left testicular torsion, and epididymal cyst was found bilaterally (Figure 1A and 1B).

In laboratory tests, the testicular tumor markers including lactate dehydrogenase (LDH), human chorionic gonadotropin (HCG), and alpha-fetoprotein (AFP), blood parameters, urine analysis and the other biochemical tests were within reference ranges.

Non-steroid analgesics were prescribed for scrotal pain and patient was discharged. The same day later the patient was admitted again at emergency department with the same symptoms. The day after, surgical operation was carried out through a scrotal incision to remove the mass. The paratesticular mass was found to be a simple epididymal cyst that was excised intact (Figure 2A). Histological examination showed the cyst wall was lined by columnar epithelium. As a result of these findings, a pathological diagnosis of epididymal cyst was made (Figure 2B). After two months patient referred to pediatric sur-



FIGURE 3. Postoperative control scrotal ultrasonogram, the size of epididymal cyst on the right epididymis is 4,5x3mm. Upper arrow shows vaz deferens, the other shows cyst.

geon for postoperative check-up. Physical examination showed a round small cyst palpated on the right epididymis while left hemiscrotum was without any pathological findings. A scrotal ultrasonography was performed which revealed a cyst in the right epididymis measuring 4.5x3 mm. (Figure 3).

There was no cyst in kidneys or other organs in abdomen. Again the tumor markers, the other blood parameters, urine analysis, and biochemical tests were unremarkable. The patient did not have any additional comorbid disease or history of exposure to diethylstilboestrol, cryptorchidism, cystic fibrosis or von Hippel-Lindau disease. The follow-up period of the patient is still ongoing.

DISCUSSION

Unilateral epididymal cysts are common and happen at all ages. They are fluid filled cysts arising from the outflow duct of the testis (the epididymis). They are most often felt as a pea-sized swelling at the top part of the testis but they can become larger. Sometimes they cause acute scrotum in children (3). There are few published reports on bilateral epididymal cysts in childhood, in the literature. Herein, we reported a case of bilateral epididymal cysts.

The pathophysiology of epididymal cysts is still unknown but there are some reports that these cysts were related to an altered hormonal environment (1). These lesions are different ultrasonographi-

cally and pathologically from the multicystic/solid epididymal cystadenomas that occur in von Hippel-Lindau disease (4). Additionally, sometimes spontaneous resolution can occur in pediatric population, and surgical intervention is rarely needed (5). Medical treatment options are the first line of therapy, as in our case. Still, the conservative treatment may sometimes be ineffective and surgery has to be performed to relieve an acute scrotum symptoms.

Epididymal cysts are diagnosed on physical examination. They are palpated as extratesticular masses but also they are characteristically smooth, round, and located within the epididymis. For differential diagnosis, laboratory tests and scrotal ultrasonography should be performed. These tests help us to make the distinction between epididymal cyst and testicular cancer. If a epididymal cyst is diagnosed, there should be no high level of LDH, HCG, and AFP in the laboratory tests. As radiological, in ultrasonography examination, epididymal cysts appear simple or minimally complex cysts and they can be diagnosed easily (5).

The treatment options depend on patients' findings. Most epididymal cysts involute with time (6, 7). Conservative treatment options are usually used for palliation (8). Epididymal cysts are treated when they cause symptoms like acute scrotum, scrotal and/or inguinal pain (8). Primary excision is performed to remove the cyst or cysts (8). The incision is performed through a median raphe or a unilateral transverse scrotal incision to deliver the testis. Great care has to be taken in children and younger men of reproductive age because the operation to remove an epididymal cyst may cause scar tissue to form and block the outflow duct of the testis. Children need to consider this risk. In the surgery of epididymal cyst in children, microsurgical techniques can be used by using optical magnification glasses (5). We used 4 optical magnification glasses during surgery. Epididymal cysts can be drained with a syringe under local anaesthetic but this is not advised because epididymal cysts can return and there is a risk of introducing infection each time the cysts are needled and also this includes infection risk of cyst. Sclerotherapy is the other option for treatment but there is not enough study that has not been reported efficiency of this treatment on children (9, 10).

Although diagnosing epididymal cyst may not represent significant problem, it is important to make the distinction between epididymal cyst and testicular cancer in childhood. Conservative treatment options are the first choice of treatment, but when surgery is needed microsurgical techniques are safe and effective for epididymal surgery in children.

REFERENCES

1. Agarwal PK, Palmer JS. Testicular and paratesticular neoplasms in prepubertal males. *J Urol* 2006;176:875-81.
2. Wein, Kavoussi, Novick, Partin, Peters: *Campbell's Urology*, 10th ed. Philadelphia, PA, Saunders, 2011, p 3060-1.
3. Rioja J, Sánchez-Margallo FM, Usón J, Rioja LA. Adult hydrocele and spermatocele. *BJU Int.* 2011;107:1852-64.
4. Choyke PL, Glenn GM, Wagner JP, Lubensky IA, Thakore K, Zbar B, Linehan WM, Walther MM. Epididymal cystadenomas in von Hippel-Lindau disease. *Urology.* 1997;49:926-31
5. Kauffman EC, Kim HH, Tanrikut C, Goldstein M. Microsurgical spermatocelectomy: technique and outcomes of a novel surgical approach. *J Urol.* 2011;185:238-42.
6. Homayoon K, Suhre CD, Steinhardt GF. Epididymal cysts in children: natural history. *J Urol.* 2004;171:1274-6.
7. Chillon Sempere FS, Domínguez Hinarejos C, Serrano Durba A, Estornell Moragues F, Martínez-Verdúch M, García Ibarra F. Epididymal cysts in childhood. *Arch Esp Urol.* 2005; 58: 325-8.
8. Erikci V, Hosgor M, Aksoy N, Okur O, Yıldız M, Dursun A, Demircan Y, Ornek Y, Genisol I. Management of epididymal cyst in childhood. *J Pediatr Surg.* 2013;48:2153-6.
9. Jahson S, Sandblom D, Holmång S. A randomized trial comparing 2 doses of polidocanol sclerotherapy for hydrocele or spermatocele. *J Urol.* 2011;186:1319-23.
10. Niedzielski J, Miodek M, Krakos. Epididymal cysts in childhood-conservative or surgical approach? *Pol Przegl Chir.* 2012; 84: 406-10.